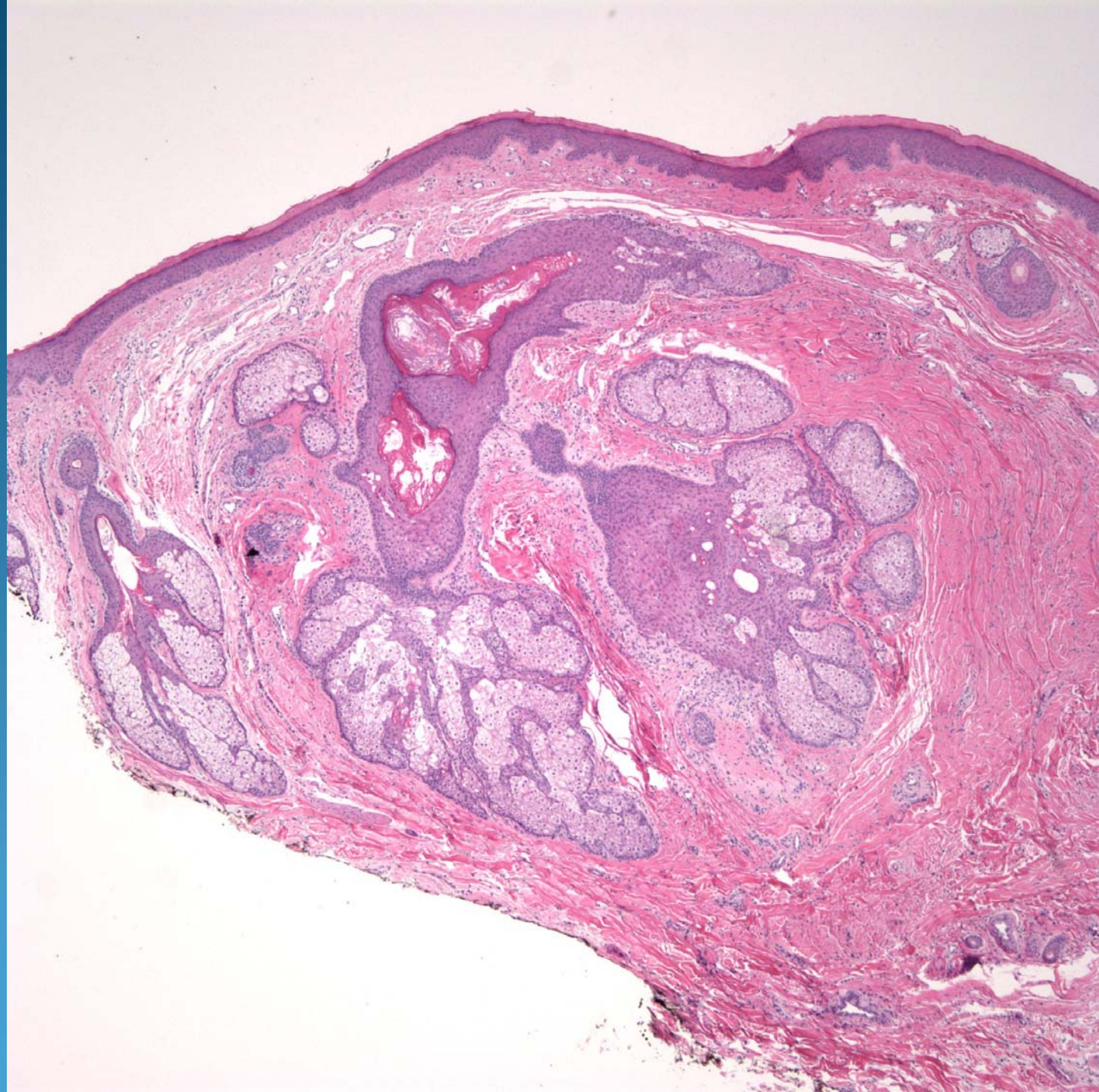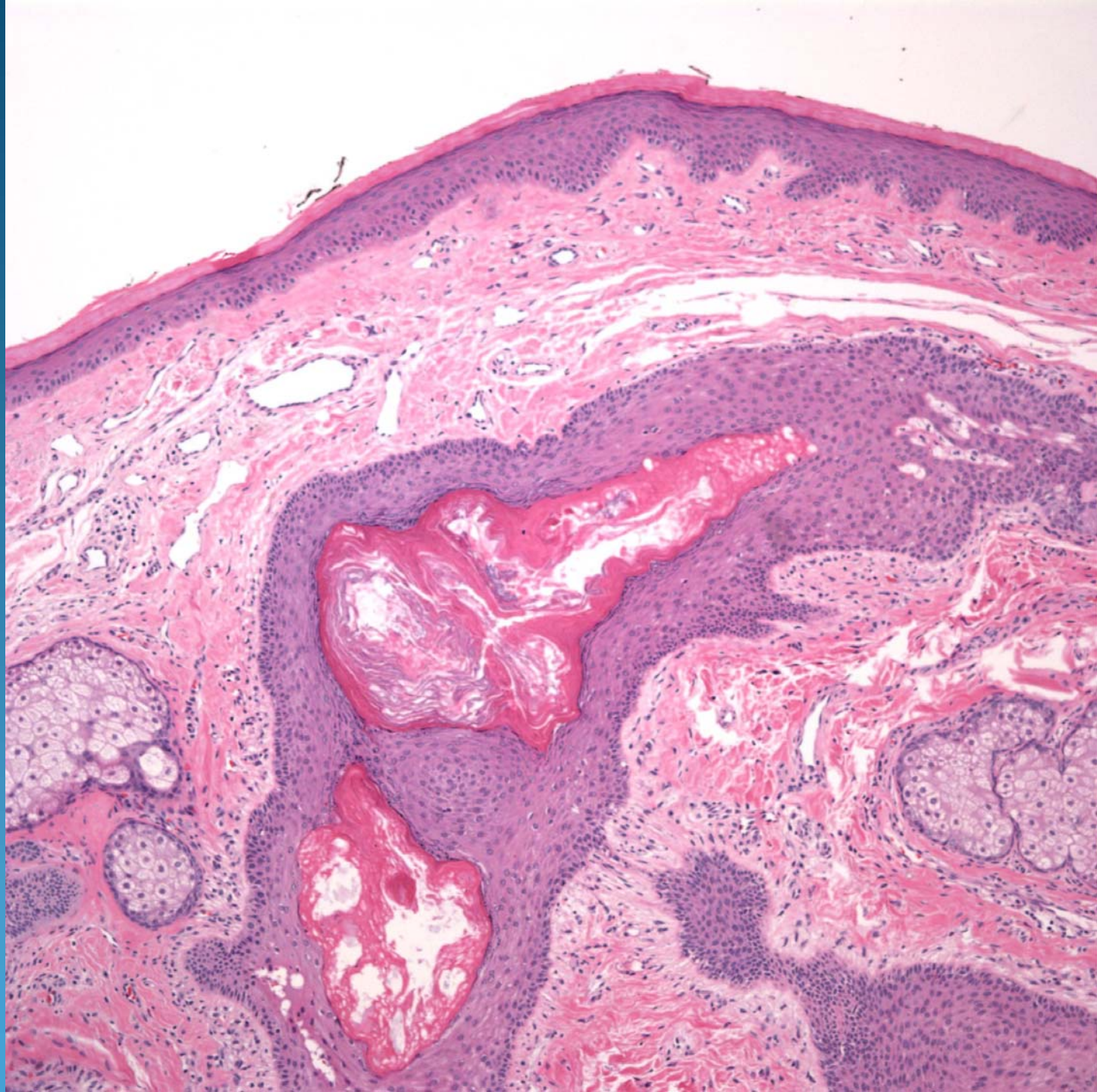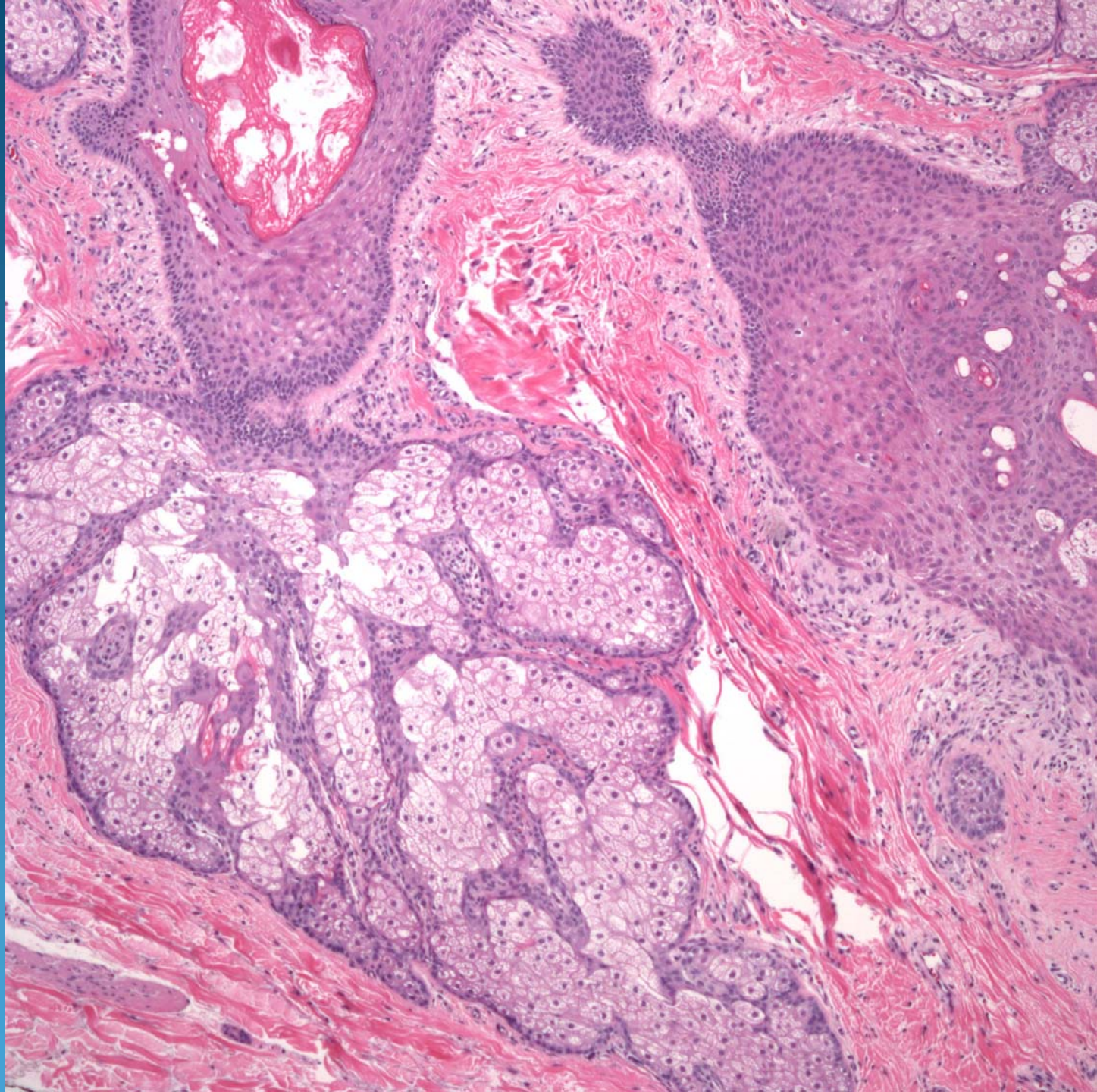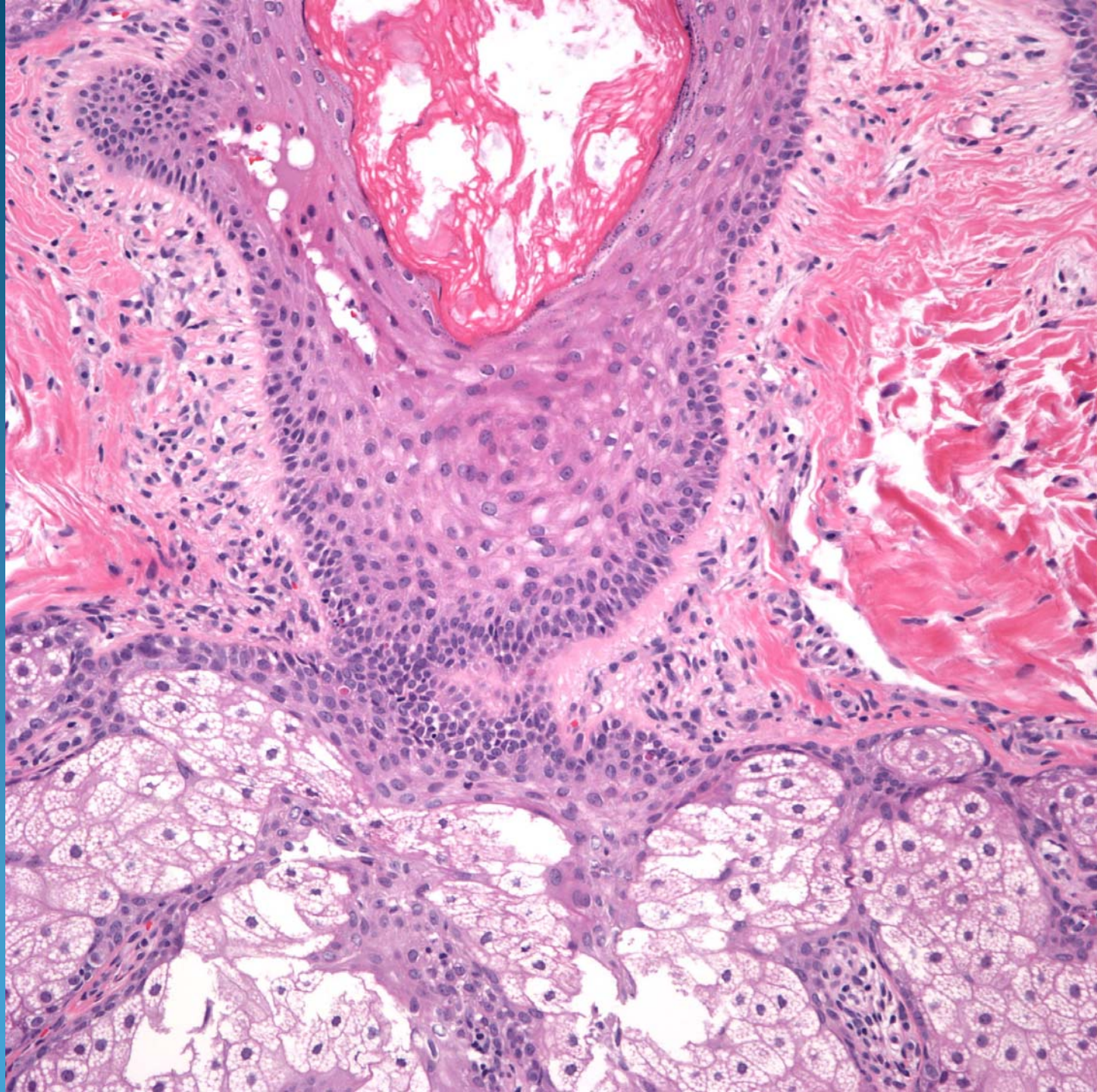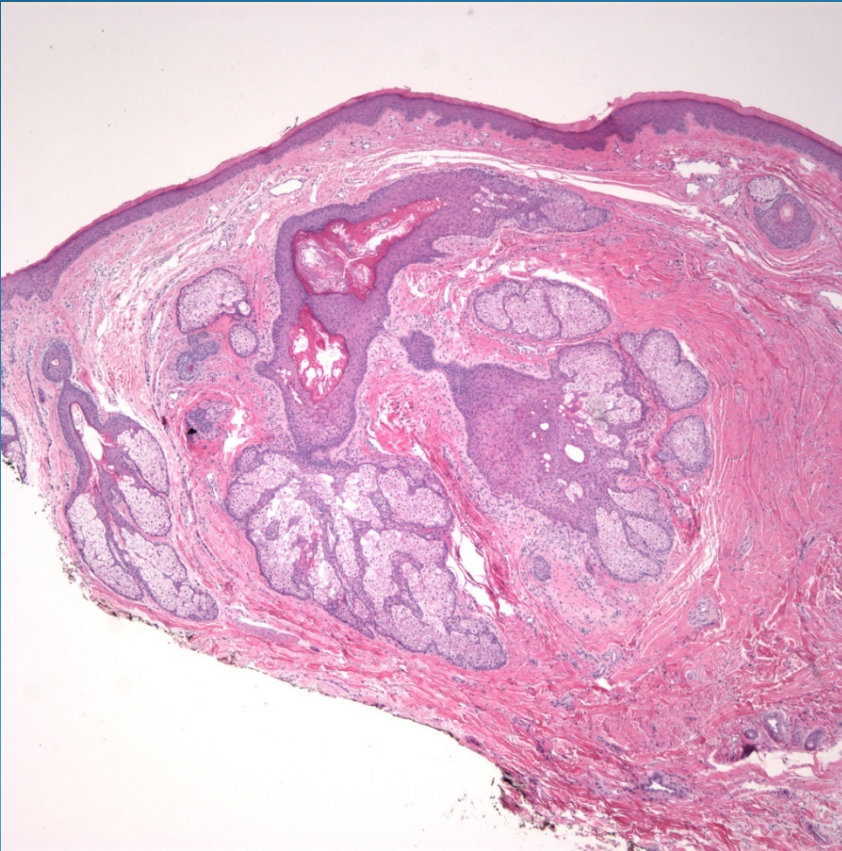


Trichofolliculoma

Pearls



- Dilated hair follicle with several pilosebaceous units emptying into it
- Dermal circumscribed tumor which may show epidermal attachment
- Characteristic clinical presentation